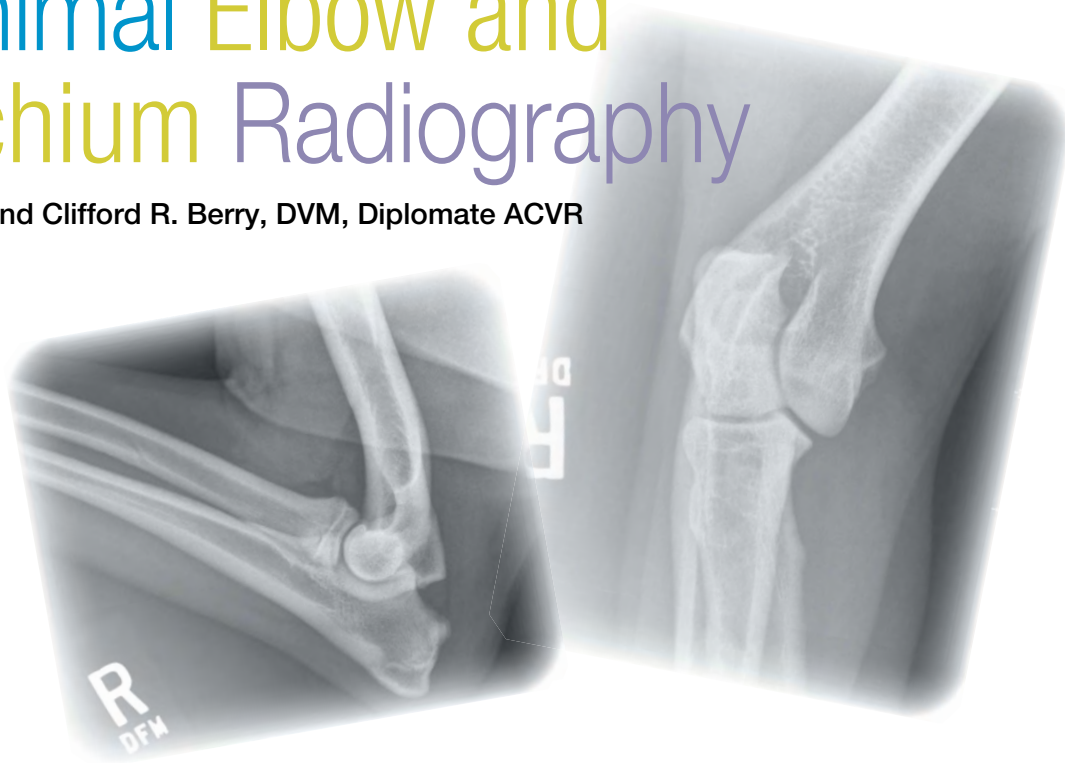




Small Animal Elbow and Antebrachium Radiography

Danielle Mauragis, CVT, and Clifford R. Berry, DVM, Diplomate ACVR



This is the sixth article in our **Imaging Essentials** series, which is focused on providing comprehensive information on radiography of different anatomic areas of dogs and cats. The following articles are available at todaysveterinarypractice.com:

- **Small Animal Thoracic Radiography** (September/October 2011)
- **Small Animal Abdominal Radiography** (November/December 2011)
- **Small Animal Pelvic Radiography** (January/February 2012)
- **Small Animal Radiography: Stifle Joint & Crus** (March/April 2012)
- **Small Animal Radiography of the Scapula, Shoulder, & Humerus** (May/June 2012)

In dogs and cats, elbow and antebrachial radiographs are used to evaluate:

- Traumatic injuries
- Soft tissue swelling
- Any potential cause of a thoracic limb lameness.

High-quality, correctly positioned, and collimated radiographs are required in order to accurately assess the area of interest. This is especially true if surgical planning is required. These studies should not be used to survey a thoracic limb.

PROJECTIONS

The elbow or antebrachium radiographic evaluation should include no less than mediolateral and craniocaudal projections. This is considered the current standard of care. A single radiographic projection of both thoracic limbs of the dog/cat in sternal recumbency is NOT acceptable for evaluating the elbow or antebrachium.

Additional projections may aid in the diagnosis of specific disease conditions or evaluation of certain anatomic areas. Obtaining the projections described in this article will provide a consistent, repeatable method for obtaining diagnostic-quality radiographs of these areas.

ROUTINE VIEWS: ELBOW Mediolateral Projection

For a mediolateral image, the dog or cat is positioned in lateral recumbency with the affected limb and area of interest against the table.

- The affected thoracic limb is taped and pulled cranially, in a neutral position, away from the thoracic cavity (**Figure 1**).
- A triangular sponge (**Figure 1B**) is placed dorsally under the scapula to lift the thoracic spine. This positioning device angles the humerus in a proximal (away from the table) to distal (closer to the table)

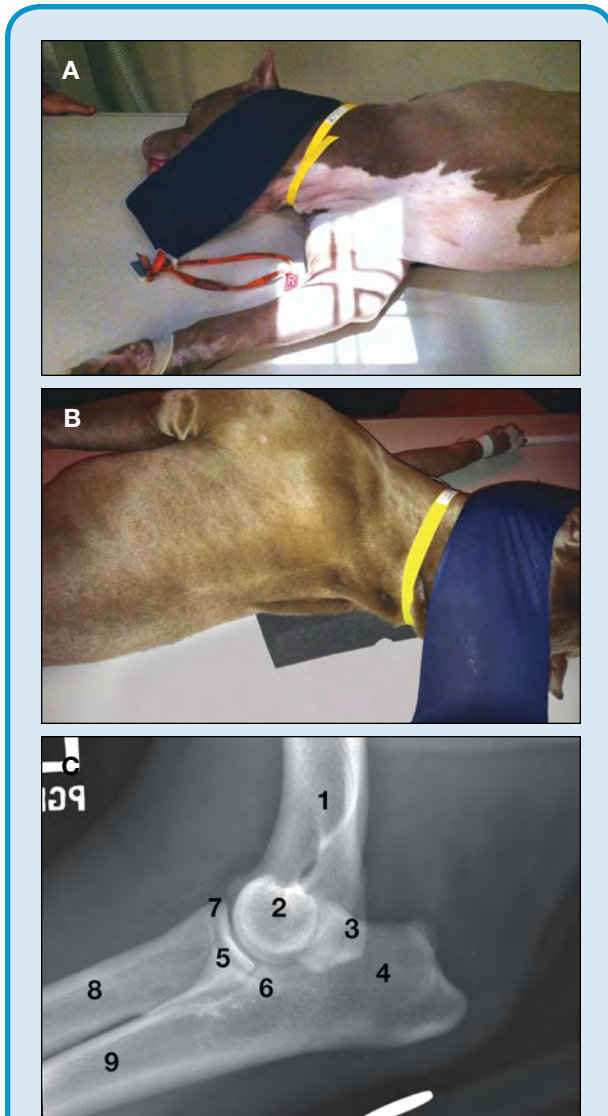


Figure 1. (A) Dog positioned for a mediolateral radiograph of the elbow. (B) Sponge placed under the shoulder to ensure straight positioning of the elbow. (C) Radiograph of an elbow with no abnormalities. 1 = distal diaphysis of the humerus; 2 = humeral condyle with superimposed epicondyles (not seen); 3 = anconeal process of the ulna superimposed over the medial epicondyle of the humerus; 4 = tuber olecranon; 5 = medial coronoid process of the ulna superimposed over the radial head; 6 = lateral coronoid process of the ulna; 7 = cranial aspect of the radial head of the radius; 8 = proximal diaphysis of the radius; 9 = proximal diaphysis of the ulna

fashion, aligning the condyle and laterally positioning the elbow.

- The unaffected limb is taped and pulled caudally so that it lies along the thoracic cavity, preventing superimposition between the thoracic limbs.
- Collimation is set by palpating the humeral condyle and placing the center of the collimation beam at the distal point of the condyle (medial condyle can be readily palpated without lifting the elbow).

Craniocaudal Projection

For the orthogonal image, the elbow is imaged in a craniocaudal direction, which reduces magnification and geometric distortion.

- The dog or cat is positioned in ventral recumbency, with the affected thoracic limb pulled cranially, placing the elbow in the center of the x-ray cassette/imaging detector.
- The unaffected limb is left in a natural position and the patient's head is placed on this limb (**Figure 2**). This rotates the affected limb, which optimizes the position of the elbow's olecranon.
- Large-breed dogs can be placed in a V-trough to help keep the dog upright. Make sure the unaffected elbow and head are outside of the trough to avoid superimposition artifacts.

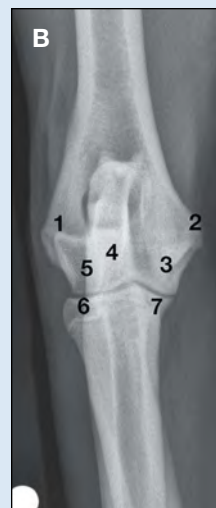


Figure 2. (A) Dog positioned for a caudocranial radiograph of the elbow. (B) Radiograph of an elbow with no abnormalities. 1 = lateral epicondyle of the humerus; 2 = medial epicondyle of the humerus; 3 = trochlea (articular surface of the humerus opposite the articular surface of the medial coronoid process of the ulna); 4 = olecranon of the ulna superimposed over the midportion of the humeral condyle; 5 = capitulum (articular surface of the humerus opposite the articular surface of the radial head); 6 = lateral aspect of the radial head; 7 = medial coronoid process of the ulna

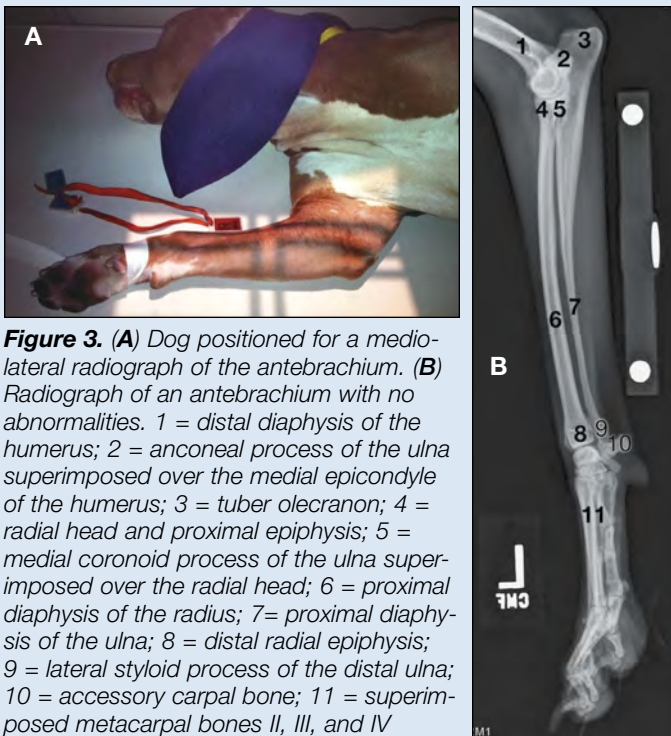


Figure 3. (A) Dog positioned for a mediolateral radiograph of the antebrachium. (B) Radiograph of an antebrachium with no abnormalities. 1 = distal diaphysis of the humerus; 2 = anconeal process of the ulna superimposed over the medial epicondyle of the humerus; 3 = tuber olecranon; 4 = radial head and proximal epiphysis; 5 = medial coronoid process of the ulna superimposed over the radial head; 6 = proximal diaphysis of the radius; 7 = proximal diaphysis of the ulna; 8 = distal radial epiphysis; 9 = lateral styloid process of the distal ulna; 10 = accessory carpal bone; 11 = superimposed metacarpal bones II, III, and IV

- The humeral condyle/epicondyles should be at the center of the collimation beam.

An alternative technique positions the patient in lateral recumbency, with the affected elbow away from the table.

- The affected limb is placed on sponges, aligning the carpus, antebrachium, elbow, and shoulder joint parallel to the table.
- The cassette/detector is then placed caudal to the limb and secured using positioning tape and sandbags.
- For this technique, the x-ray tube head is rotated 90 degrees toward the affected limb (x-ray travel is now parallel to the table, not perpendicular). The beam is centered on the humeral condyle/epicondyles.

ROUTINE VIEWS: ANTEBRACHIUM

Mediolateral Projection

For a lateral image, the patient is positioned on the table in lateral recumbency, with the affected limb against the table (**Figure 3**).

- The thoracic limbs should be taped separately with the affected limb pulled cranially and away from the thoracic cavity in a neutral position (elbow at approximately 100 degrees of flexion).
- The unaffected limb is pulled caudally so that it lies along the thoracic cavity.
- The collimator beam is centered halfway between the elbow and carpal joints.

Measuring the Elbow & Antebrachium for Radiographic Technique

Craniocaudal Projection: Measure the thickness at the level of the humeral condyle in the cranial to caudal direction.

Mediolateral Projection: Measure the thickness at the level of the humeral condyle for the elbow and antebrachium.

Craniocaudal Projection

For the orthogonal view, the antebrachium is imaged in a craniocaudal direction, which reduces magnification and distortion.

The ability of the x-ray machine to perform horizontal beams and manipulate angulation of the tube will determine how the craniocaudal projection is achieved. The x-ray tube can be positioned in a:

- **Vertical location:** X-ray beam perpendicular to the table; patient positioned in *sternal recumbency* or
- **Horizontal location:** X-ray beam parallel to the table; patient positioned in *lateral recumbency*.

There is a tradeoff between these two techniques: The easiest technique for use in both the dog and cat is sternal recumbency positioning, which pulls the affected thoracic limb cranially. However, the patient may lay more still in lateral recumbency. Both techniques produce high quality images.

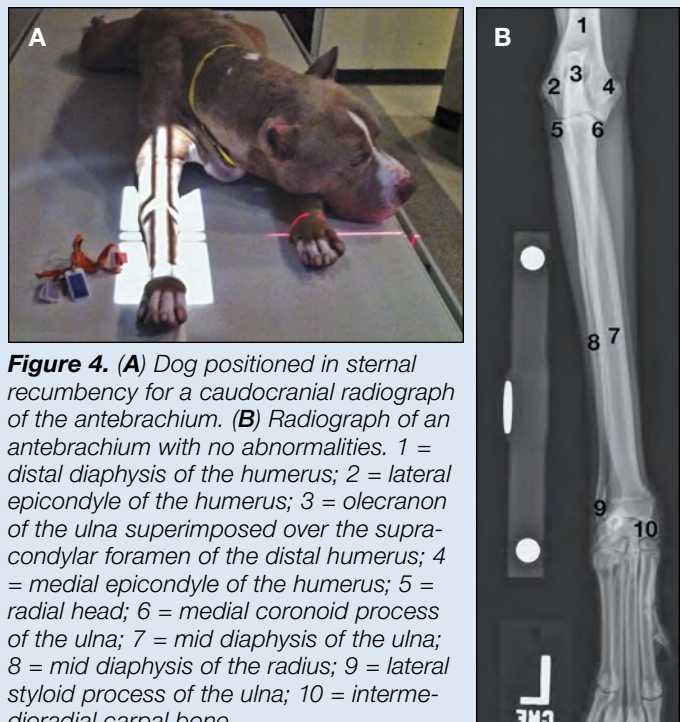


Figure 4. (A) Dog positioned in sternal recumbency for a caudocranial radiograph of the antebrachium. (B) Radiograph of an antebrachium with no abnormalities. 1 = distal diaphysis of the humerus; 2 = lateral epicondyle of the humerus; 3 = olecranon of the ulna superimposed over the supracondylar foramen of the distal humerus; 4 = medial epicondyle of the humerus; 5 = radial head; 6 = medial coronoid process of the ulna; 7 = mid diaphysis of the ulna; 8 = mid diaphysis of the radius; 9 = lateral styloid process of the ulna; 10 = intermediodiaphyseal carpal bone

IDENTIFYING ELBOW DYSPLASIA

Elbow dysplasia is a group of developmental disorders that include:

- An ununited anconeal process of the ulna
- Fragmentation of the medial coronoid process of the ulna
- Osteochondrosis/osteochondritis dissecans of the medial aspect of the humeral condyle.

Elbow dysplasia occurs in young, rapidly growing, large- to giant-breed dogs. Additional radiographic projections may be needed in order to define extent of pathology or isolate a given anatomic part, allowing easier identification of subtle pathology.

Flexed Mediolateral Projection

This view allows direct evaluation of the anconeal process, which helps:

- Confirm an ununited anconeal process of the proximal ulna
- Identify early degenerative change (enthesiophyte formation) associated with the anconeal process.

However, this view rotates the proximal ulna and obscures the margins of the medial coronoid process of the proximal ulna. Therefore, this radiographic projection should only be used to evaluate the anconeal process; not other aspects of the elbow.

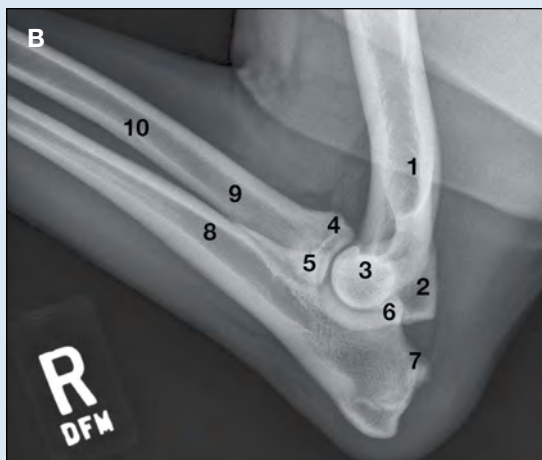


Figure 5. (A) Dog positioned for a flexed mediolateral projection of the elbow. (B) Radiograph of an elbow with no abnormalities. 1 = distal diaphysis of the humerus; 2 = caudal margin of the medial epicondyle of the humerus; 3 = humeral condyle with superimposed epicondyles (not visualized); 4 = radial head; 5 = medial coronoid process of the ulna; 6 = anconeal process of the ulna; 7 = tuber olecranon; 8 = proximal diaphysis of the ulna; 9 = proximal diaphysis of the radius; 10 = nutrient canal of the radius along the caudal interosseous border

- The dog is placed in lateral recumbency with the affected limb against the table.
- A sponge is placed dorsally under the scapula to lift the thoracic spine, helping position the elbow laterally (**Figure 1B**, page 46).
- The affected limb is taped and pulled cranially away from the thoracic cavity.
- The elbow is then flexed cranially, with the distal part of the limb (manus/paw) placed near the mandible or under the skull (**Figure 5**).
- The area of interest should not be near or superimposed over the thoracic inlet or sternum.
- As with other elbow views, the field of view should include the proximal third of the radius and ulna and distal third of the humerus.

Pronated Craniocaudal Evaluation

This view helps evaluate the:

- Trochlea of the humeral condyle
- Medial coronoid process of the ulna
- Adjacent subchondral bone.

The dog can be placed in either sternal or lateral recumbency (**Figure 6**), but the sternal technique is the easiest.

- The elbow should be placed in the same position as for a routine caudocranial projection (affected thoracic limb pulled cranially).
- The olecranon should then be rotated approximately 10 to 15 degrees laterally. This shifts the position of the elbow laterally.
- The image should include the same anatomy as in a routine craniocaudal image, with the olecranon in an oblique lateral position so the trochlea (medial humeral condyle) and the medial coronoid process (ulna) are more apparent.

Proximomedial to Distolateral 45-Degree Oblique Projection

This view helps evaluate the medial coronoid process of the ulna.

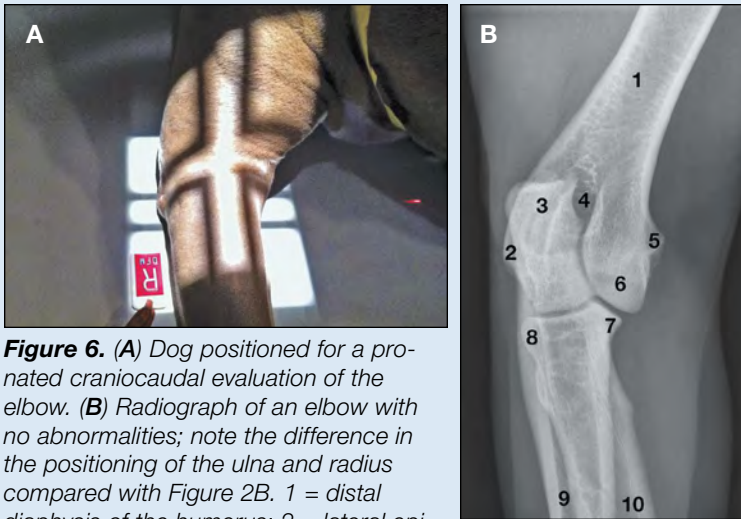


Figure 6. (A) Dog positioned for a pronated craniocaudal evaluation of the elbow. (B) Radiograph of an elbow with no abnormalities; note the difference in the positioning of the ulna and radius compared with Figure 2B. 1 = distal diaphysis of the humerus; 2 = lateral epicondyle of the humerus; 3 = olecranon of the ulna; 4 = supracondylar foramen of the distal humerus; 5 = medial epicondyle of the humerus; 6 = trochlea of the humerus; 7 = medial coronoid process of the ulna; 8 = lateral border of the radial head superimposed over the lateral cortex of the proximal ulnar diaphysis; 9 = diaphysis of the ulna; 10 = diaphysis of the radius

- The dog is placed in the same position as for a routine mediolateral elbow projection.
- With the affected limb against the cassette/table, the distal limb (manus/paw) is angled away from the table (upward) toward the x-ray tube at a 40- to 45-degree angle relative to the table (Figure 7).
- Positioning sponges or a large 45-degree triangular sponge is used to maintain the distal thoracic limb at this angle.
- The elbow remains in contact with the cassette/table. The limb should be taped to the table, keeping the limb taut but not lifting the elbow away from the table.
- Collimation is the same as in mediolateral and flexed mediolateral projections.

- The halfway point between the elbow and carpal joint should be at the center of the collimator beam.

Lateral Recumbency

- The affected limb is pulled cranially and away from the table; then sponges are placed along the medial side of the limb, positioning the affected limb level with the shoulder joint.
- The cassette/detector is placed cranially and secured.
- For this technique, the x-ray tube head is rotated 90 degrees toward the affected limb. The x-ray beam is centered in a proximodistal direction at a mid point between the cubital carpal joints, with the horizontal line of the collimator light aligned with the midline of the radius/ulna.

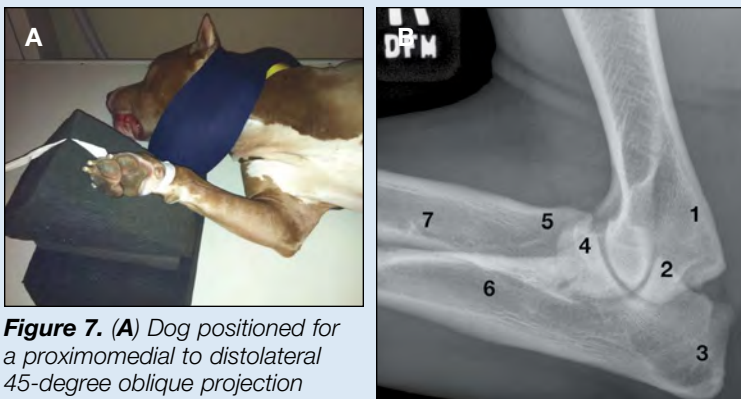


Figure 7. (A) Dog positioned for a proximomedial to distolateral 45-degree oblique projection of the elbow. (B) Radiograph of an elbow with no abnormalities. 1 = medial epicondyle of the distal humerus; 2 = anconeal process of the ulna; 3 = tuber olecranon of the ulna; 4 = medial coronoid process of the ulna; 5 = radial head; 6 = diaphysis of the ulna; 7 = diaphysis of the radius

QUALITY CONTROL

Use a three-step approach to determine the quality of a diagnostic image:

1. Is the technique adequate (appropriate exposure and development factors)?
2. Is the positioning anatomically correct and straight?
3. Is the correct anatomy present within the image (see below)?

Elbow

Once the desired technique and positioning has been attained, make sure the appropriate anatomy is included.

- **The mediolateral and craniocaudal projections of the elbow** should include the distal third of the humerus and proximal third of the radius/ulna.

Sternal Recumbency (Figure 4, page 47)

- The affected limb is pulled cranially, placing the affected antebrachium at the center of the cassette/detector.
- The unaffected limb is left in a natural, bent position with the patient's head placed on it. This rotates the affected limb, optimizing the position of the olecranon of the elbow and carpus.
- The patient can be placed in a V-trough to help keep the patient upright. Make sure the unaffected elbow and head are outside of the trough to avoid superimposition artifacts.

When Angles Are Off

In dogs with angular limb deformities, the elbow and carpal joint may not be adequately aligned for accurate assessment. Placing the limbs at unusual angles may be required to correctly align the x-ray beam with the joint space.

- **The mediolateral projection** of the epicondyles of the humerus should be superimposed, with joint spaces between the humerus and radius, radius and humerus, and ulna and humerus (**Figures 1B and 1C**).
- **The craniocaudal projection** should align the tuber olecranon and proximal portion of the ulna, superimposing them over the center of the humeral condyle and supracondylar foramen of the distal humerus (**Figures 2B and 2C**).
- **Note:**
 - » When evaluating the craniocaudal image, the capitulum (lateral) and trochlea (medial) join together centrally at a junction site that points toward the proximal aspect of the humerus (metaphysis and diaphysis).
 - » This junction site between the trochlea and capitulum should be superimposed over the middle of the olecranon, between the medial and lateral cortices, which allows the practitioner to evaluate whether or not incomplete ossification of the distal humeral condyle is present. If present, a radiolucent line is seen extending from the joint surface to the supracondylar foramen.

Antebrachium

As above, once the desired technique and positioning have been attained, make sure the appropriate anatomy is included.

- **The mediolateral and craniocaudal projections of the antebrachium** should include the mid metacarpal level and distal third of the humerus.
- **The mediolateral projection** should show the cubital and carpal joints in true lateral position; not obliqued toward or away from the table/cassette. Keep in mind, however, that x-ray beam divergence will decrease visualization of the joint spaces when compared to

Radiographic Technique

The focus of the articles in this series has been on technical positioning of a patient rather than the factors that impact actual generation of the image. However, techniques have been suggested throughout the series that provide a frame of reference for obtaining a diagnostic radiograph. See **Small Animal Thoracic Radiography** (September/October 2011) for a more in-depth discussion on radiographic technique.

images from the dog obtained with the x-ray beam centered directly over the individual joint(s).

- **The craniocaudal projection** should superimpose and center the tuber olecranon of the ulna within the distal humeral condyle. The carpus should be flat against the table/cassette and should not be rotated in either a supinated or pronated position.
- **Note:**
 - » Radiographic projections of the antebrachium evaluate the radius and ulna in their entirety.
 - » This projection should not replace radiographic examination of the elbow or carpal joints. ■

Suggested Reading

- Burk RL, Feeney DA. *Small Animal Radiology and Ultrasonography: A Diagnostic Atlas and Text*, 3rd ed. Philadelphia: Saunders Elsevier, 2003.
- Kealy JK, McAllister H, Graham JP. *Diagnostic Radiology and Ultrasonography of the Dog and Cat*, 5th ed. Philadelphia: Saunders Elsevier, 2011.
- Sirois M, Anthony E, Mauragis D. *Handbook of Radiographic Positioning for Veterinary Technicians*. Clifton Park, NY: Delmar Cengage Learning, 2010.
- Thrall DE (ed). *Textbook of Veterinary Radiology*, 5th ed. Philadelphia: Saunders Elsevier, 2008.
- Thrall DE, Robertson ID. *Atlas of Normal Radiographic Anatomy and Anatomic Variants in the Dog and Cat*. Philadelphia: Elsevier Saunders, 2011.



Danielle Mauragis, CVT, is a radiology technician at University of Florida College of Veterinary Medicine. She teaches veterinary students all aspects of the physics of diagnostic imaging, quality control of radiographs, positioning of small and large animals, and radiation safety. Ms. Mauragis coauthored the *Handbook of Radiographic Positioning for Veterinary Technicians* (2009) and was the recipient of the Florida Veterinary Medical Association's 2011 Certified Veterinary Technician of the Year Award. This award recognizes an individual for the many outstanding contributions that person has made to the overall success of the veterinary practice operated or staffed by an FVMA member veterinarian.



Clifford R. Berry, DVM, Diplomate ACVR, is a professor in diagnostic imaging at the University of Florida College of Veterinary Medicine. His research interests include cross-sectional imaging of the thorax, nuclear medicine applications in veterinary medicine, and biomedical applications of imaging in human and veterinary medicine. Dr. Berry has been a faculty member at North Carolina State University and University of Missouri. He received his DVM from University of Florida and completed a radiology residency at University of California–Davis.