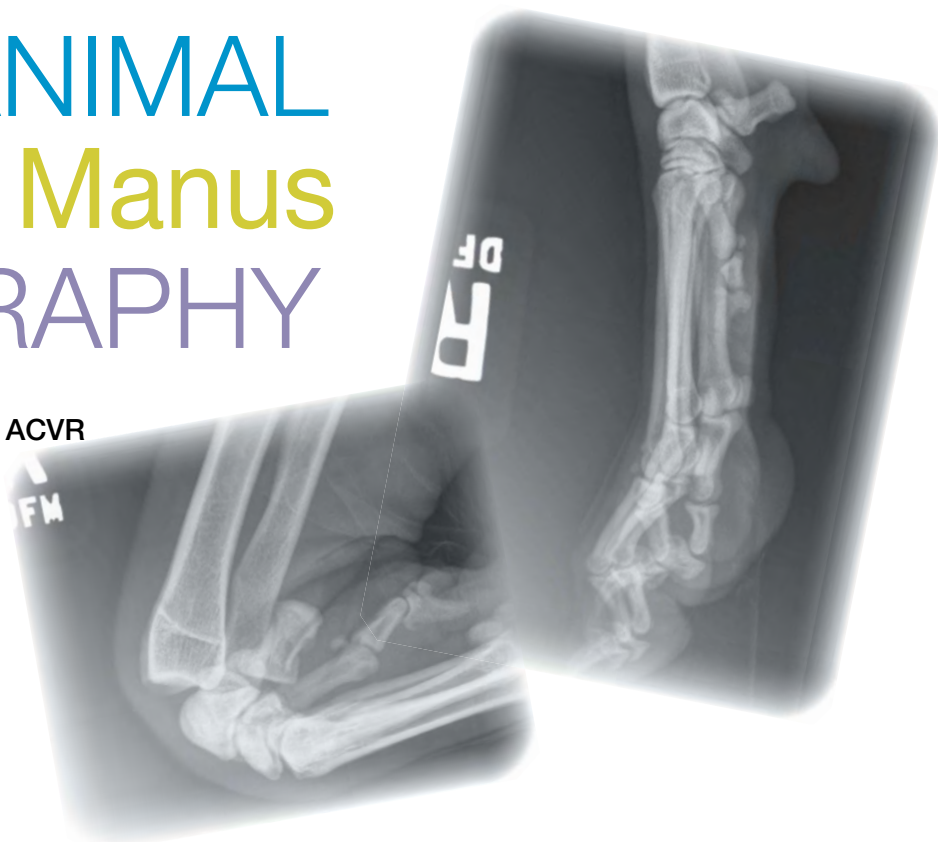




SMALL ANIMAL Carpus & Manus RADIOGRAPHY

Danielle Mauragis, CVT, and
Clifford R. Berry, DVM, Diplomate ACVR



This is the seventh article in our **Imaging Essentials** series, which is focused on providing comprehensive information on radiography of different anatomic areas of dogs and cats. The following articles are available at todaysveterinarypractice.com:

- **Small Animal Thoracic Radiography** (September/October 2011)
- **Small Animal Abdominal Radiography** (November/December 2011)
- **Small Animal Pelvic Radiography** (January/February 2012)
- **Small Animal Radiography: Stifle Joint & Crus** (March/April 2012)
- **Small Animal Radiography of the Scapula, Shoulder, & Humerus** (May/June 2012)
- **Small Animal Elbow & Antebrachium Radiography** (July/August 2012)

Radiographs of the carpus and manus are needed for evaluation of traumatic injuries and swelling or lameness.

Standard evaluation of the carpus and manus includes mediolateral and dorsopalmar projections. The additional projections described aid in diagnosis of specific disease conditions or evaluation of specific anatomic areas. Stress views are described so that ligamentous and joint capsular stability can be assessed. You should not “survey” a thoracic limb (single open leg lateral or craniocaudal radiograph).

Computed and digital radiographic techniques are sensitive to smaller parts of the anatomy (extremities of small dogs and cats), metal (bone plates, screws, intermedullary pins, etc), and collimation. Because detectors reconstruct the image based on x-ray numbers detected in each element, detector extremes are not handled accurately without artifacts. These extremes would include collimation to a small area (still the goal for radiation exposure purposes) or extreme areas of x-ray attenuation between air and metal associated with the image.

This sensitivity means that the technician needs to pay special attention to technique to avoid saturating the imaging plate, resulting in loss of all soft tissue structures or any potential artifacts.

ROUTINE PROJECTIONS

Mediolateral Projection

For the mediolateral image, the dog or cat is positioned on the table in lateral recumbency, with the affected thoracic limb positioned against the table or imaging cassette/detector.

- The affected limb is taped and pulled cranially in a neutral position away from the thoracic cavity. A small sponge may need to be placed under the elbow to keep the limb level with the detector/cassette (**Figure 1**).
- The unaffected limb is taped and pulled caudally, allowing it to lie along the thoracic cavity and preventing superimposition between the thoracic limbs.

To set collimation for the mediolateral image:

- **Carpus:** Palpate the carpus and center the collimated beam at this point, which should be at the level of the accessory carpal pad. Collimate so the field of view (FOV) includes the proximal third of the meta-

carpal bones and distal third of the radius/ulna.

- **Manus:** Collimate so the FOV is centered in the middle of the metacarpal bones and includes the digits (toe nails included), proximal to the level of the antebrachiocarpal joint.
- **Phalanges:** The mediolateral projection of the phalanges requires spreading the digits to avoid superimposition of the proximal sesamoids and digits. This can be accomplished by placing a cotton ball between each digit, taping the nail of digit II and digit V with a (approximately) 12-inch length of ½-inch adhesive tape, and pulling digit II dorsally and digit V in a palmar direction, taping these digits to the detector/cassette or table. If the digit lacks a nail, tape around the entire digit, recognizing there will be tape artifact superimposed over the digit (proximal phalanx). Radiopaque markers can be placed dorsal to the second digit and palmar to the fifth digit as well to avoid confusion (**Figure 1**).

Dorsopalmar Projection

For the dorsopalmar image, the patient is positioned on the table in ventral recumbency, with the carpus or manus of the affected limb positioned against the imaging cassette/detector to reduce magnification and geometric distortion.

- The affected limb is pulled cranially, placing the carpus, manus, or phalanges in the center of the imaging cassette/detector (**Figure 2**).
- The unaffected limb is placed in a natural position and the patient's head is placed on this limb. This positioning rotates the affected limb, optimizing the

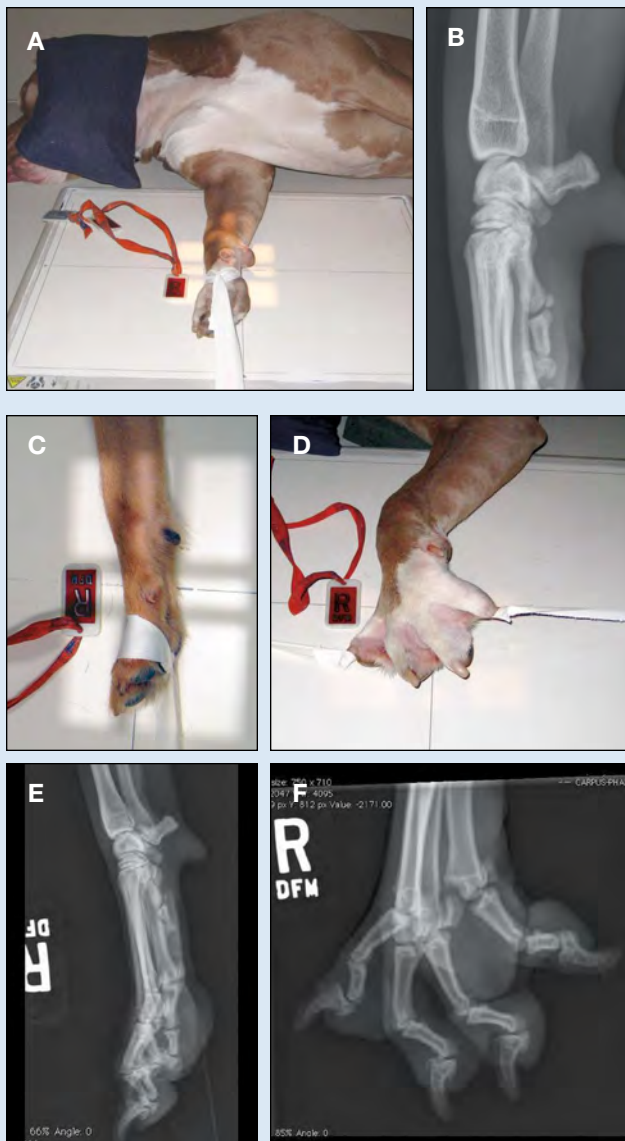


Figure 1. Dog positioned for mediolateral collimated image of carpus (**A**) and corresponding radiograph (**B**); mediolateral positioning for manus (**C**) and phalanges (**D**) and corresponding radiographic images (**E** and **F**, respectively).

MEASURING THE CARPUS & MANUS FOR RADIOGRAPHIC TECHNIQUE

- **Mediolateral projection:** Measure the thickness at the level of the carpus.
- **Dorsopalmar projection:** Measure the thickness at the level of the carpus in the dorsopalmar direction. For either projection, the techniques will use a table-top technique instead of a grid.

Radiopaque marker placement:

- **Mediolateral projection:** Marker placed dorsal to the limb within collimated area.
- **Dorsopalmar projection:** Marker placed along the lateral aspect of limb within collimated area.

Collimation:

- **Carpus:** Center the beam on the carpus, collimating to the carpus.
- **Manus:** Center on the mid metacarpi, collimating from the distal radius to the end of the digits.

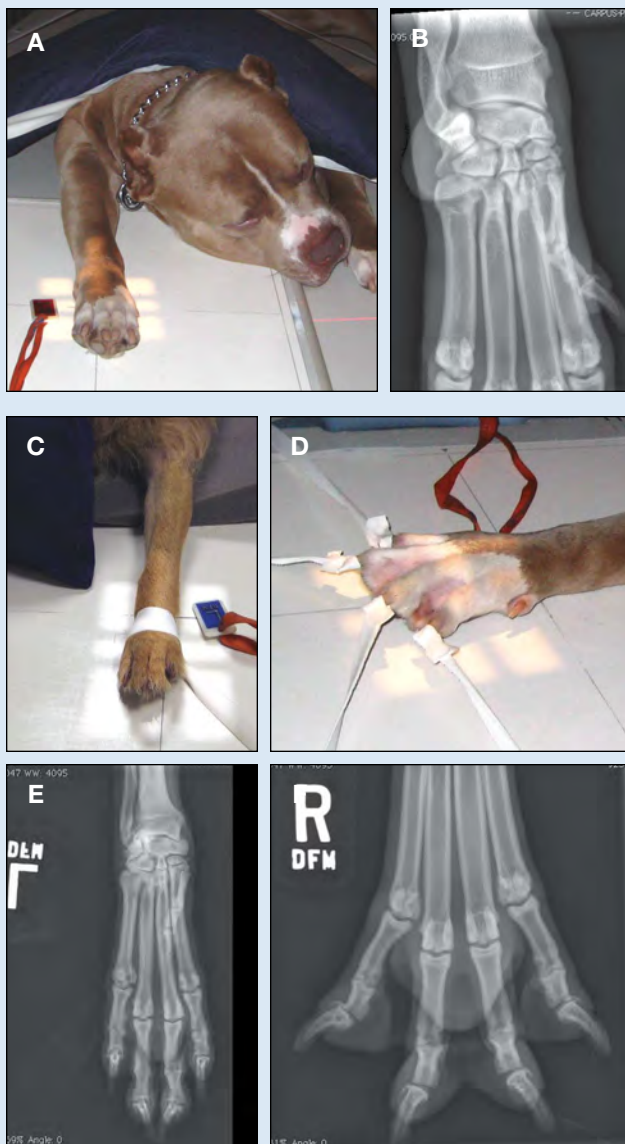


Figure 2. Dog positioned for dorsopalmar collimated image of carpus (A) and corresponding radiographic image (B); dorsopalmar positioning for manus (C) and phalanges (D) and corresponding radiographic images (E and F, respectively).

For more information regarding digital radiography artifacts, see the article, Digital Radiography Artifacts, in *Veterinary Radiology and Ultrasound*, available at vitalrads.com/pub/Digital_Radiography_Artifacts.pdf.

positioning of the manus.

- Large-breed dogs can be placed in a V-trough in order to keep the dog upright. Ensure that the unaffected limb and head are outside the V-trough to avoid summation artifacts.

To set the collimation for the dorsopalmar image:

- **Carpus:** Palpate carpus and place the center of the collimated beam at this point. Collimate so the FOV includes the proximal third of the metacarpal bones and distal third of the radius and ulna.
- **Manus:** Collimate so the FOV is centered on the mid to distal metacarpal bones and includes the digits (toe nails included) proximal to the antebrachiocarpal joint and distal radius/ulna.
- **Phalanges:** The dorsopalmar projection of the phalanges requires spreading the digits; follow the instructions for doing so under **Mediolateral Projection**.

ADDITIONAL PROJECTIONS

In some cases, additional radiographic projections of the manus and pes will be necessary. Indications for flexed mediolateral, hyperextended mediolateral, and stress dorsopalmar/plantar projections of the carpus, tarsus, carpo-metacarpal, and tarsometatarsal joints include evaluation of soft tissue injuries for possible collateral damage/rupture with resultant joint instability (**Figure 3**, page 54) and identification of articular fractures. These ancillary radiographic projections allow for the application of stress to the joints of the carpus in an effort to identify joint space widening that is encountered with damage to the soft tissue supporting structures of the joints.

Flexed Mediolateral Projection of the Carpus

- Place the patient in the mediolateral position for the affected limb.
- Flex the phalanges toward the palmar aspect of the carpus and secure with adhesive tape using a figure-eight that is applied around the metacarpal bones distally and the distal radius/ulna proximally.
- Center the FOV at the flexed carpal joint so the proximal metacarpal bones, all of the carpus, and the distal radius/ulna are included in the collimation.

Hyperextended Mediolateral Projection of the Manus for Instability

- Place the patient in the mediolateral position for the affected limb.
- Apply adhesive tape around the radius/ulna,

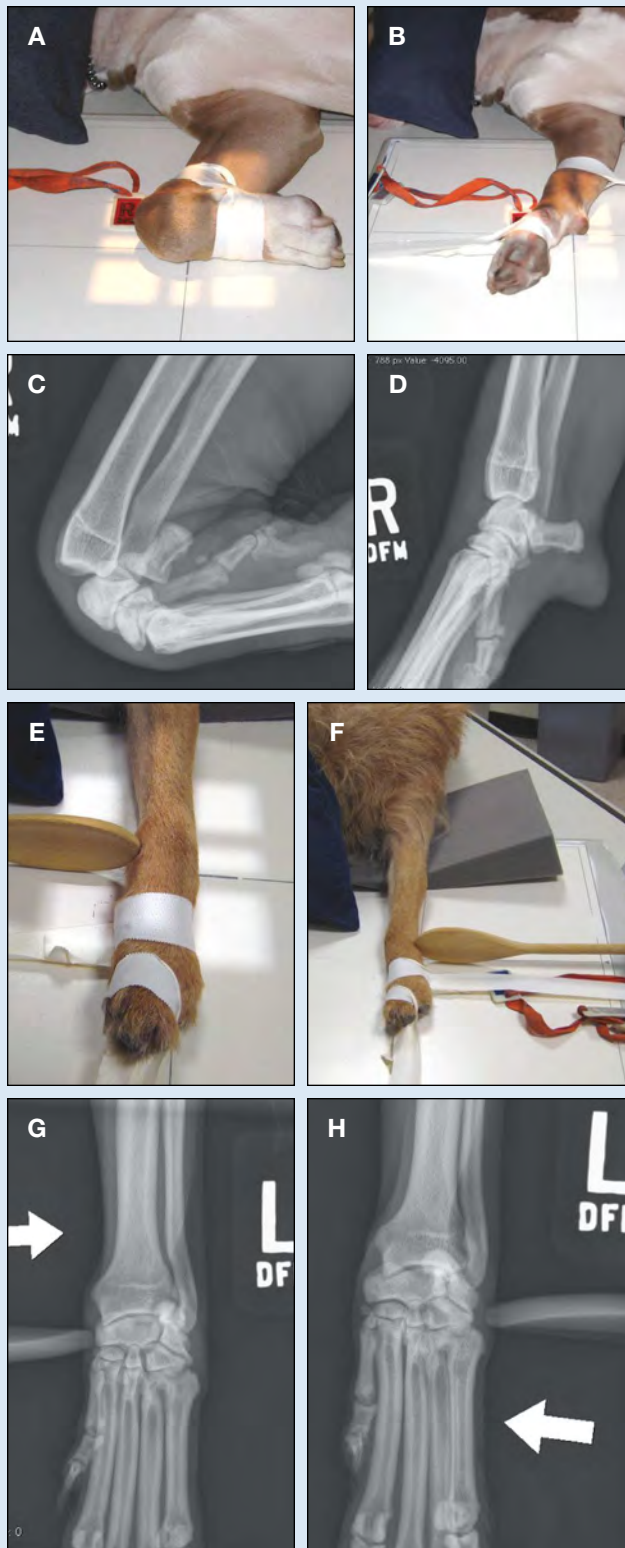

Figure 3. Dog positioned for mediolateral flexed (A) and extended (B) images of carpus and corresponding radiographic images (C and D, respectively); application of spoon for dorsopalmar medial (E) and lateral (F) stress projections and corresponding radiographs (G and H, respectively).

pull the tape caudally, and anchor to the imaging cassette/detector. Apply another strip of tape around the metacarpal bones, pulling dorsally, and anchor the tape to the cassette/detector or table. This taping results in hyperextension of the antebrachio-carpal, middle carpal, and carpo-metacarpal joints.

- Center the FOV on the carpus so the proximal metacarpal bones proximally and distal radius/ulna are included in the collimation (Figure 3).

Dorsopalmar Projection of the Carpus with Lateral & Medial Stress Applied

Stress views require additional personnel who can apply necessary pressure to the carpal joints while the exposure is taken. Those obtaining these images should follow appropriate radiation safety practices, including wearing radiation monitoring badges, leaded aprons, gloves, and thyroid shields. A wooden cooking spoon is used to apply medial or lateral stress to the carpus, identifying any collateral damage to the joint (Figure 3).

- Place the patient in the dorsopalmar position, with collimation as described to the carpus.
- Open up the collimation slightly more than it would be for a normal dorsopalmar image of the carpus in order to capture any collateral damage.
- **Lateral stress view:** This view enables identification of abnormalities on the lateral side of the carpus.
 - » Place adhesive tape around the metacarpus and pull the distal extremity distally; anchor the end of the tape to the edge of the cassette/detector or table.
 - » Place a second piece of tape around the metacarpus, pull medially, and tape to the edge of the cassette/detector or table in order to anchor the distal limb.
 - » Holding the handle of the spoon, place the edge along the medial aspect of the carpus at the level of the middle carpal joint. Push the spoon toward the lateral side gently.
 - » The exposure is taken while this pressure (stress) is being applied.
- **Medial stress view:** This view enables identification of abnormalities on the medial side of the carpus. The steps are the same as above, except that the spoon edge is placed along the lateral aspect of the carpus, with pressure applied toward the medial side.
- **Collimation** should be set to keep the hands of the person applying stress outside the primary beam, even if this person is wearing leaded gloves.

Oblique Radiographic Projection of the Carpus

Indications for oblique projections of the carpus include complex pathology in which separation

of certain bones aids in evaluating specific parts of a given carpal bone or joint surface, such as:

- Fractures
- Neoplasia, immune-mediated, or congenital anomalies
- Traumatic distal radial or ulnar premature physal closure
- Metabolic abnormalities.

In these oblique projections, the radiopaque identification marker remains along the lateral aspect of the thoracic limb (**Figure 4**).

- Place the patient in the dorsopalmar position to begin.
- **Dorsomedial to palmarolateral oblique projection:**
 - » Position the carpus in a straight dorsopalmar orientation and rotate (supinate) toward mid line approximately 35 degrees.
 - » The collimation is the same as for a dorsopalmar projection.
 - » The resulting image includes the same anatomy as the dorsopalmar projection, except that the dorsomedial and palmarolateral structures—bone and joint surfaces—are highlighted.
- **Dorsolateral to palmaromedial oblique projection:** Position the carpus in a straight dorsopalmar orientation and rotate (pronate) outward away from mid line approximately 35 degrees.

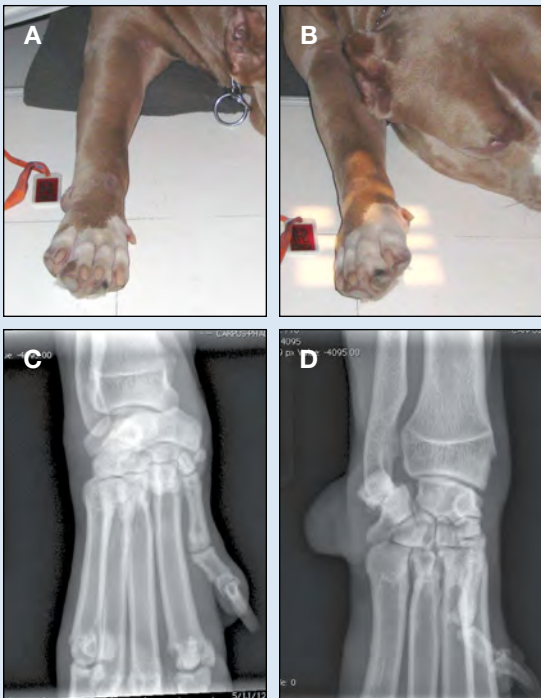
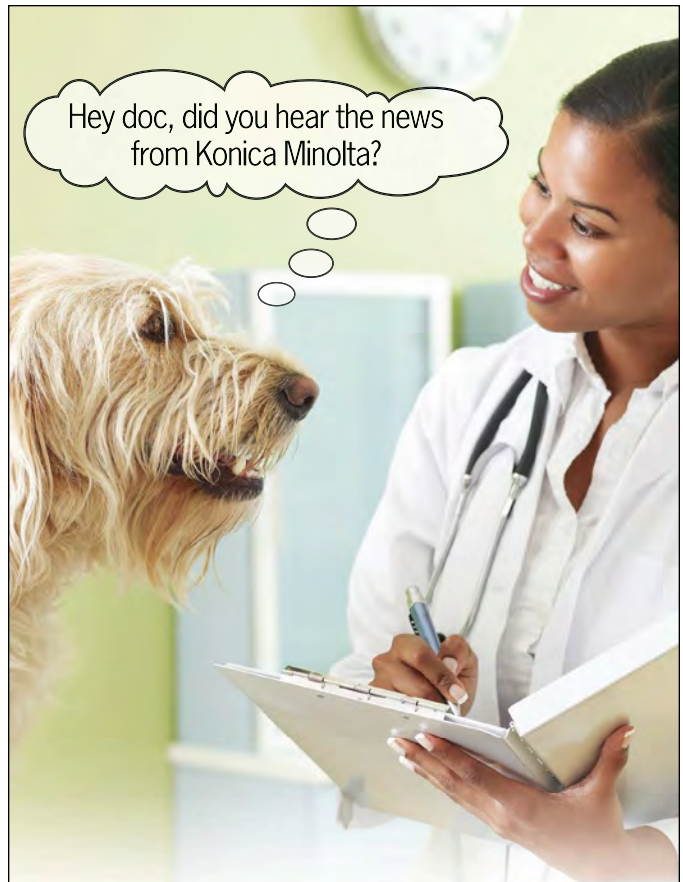
Figure 4. Dog positioned for oblique projections of carpus and corresponding radiographic images: Dorsolateral to palmarolateral oblique (**A**) and dorsomedial to palmarolateral oblique (**B**) projections and corresponding radiographic images (**C** and **D**, respectively).



Only ImagePilot With Infirmity Brings You So Much For So Little!

Designed and developed by Konica Minolta, the proven leader in digital radiography, the ImagePilot Sigma is the affordable solution for all your radiography needs. This easy-to-use desktop system is fully featured and offers you superior image quality and optimal workflow.

Infirmity is Konica Minolta's "Cloud Based" service offering the ultimate solution to meet your ImagePilot data storage and collaborative needs. Simple to use, Infirmity protects your valuable data from catastrophic loss and allows you to share images online instantly with colleagues.

ImagePilot Sigma and Infirmity... from the #1 rated manufacturer in Customer Satisfaction, Reliability and Value!



KONICA MINOLTA

Giving Shape to Ideas

Website: medical.konicaminolta.us
1 (800) 934-1034, ext. 1354

QUALITY CONTROL

When performing quality control, a technician should answer three questions about each image obtained:

1. Is the technique adequate (appropriate exposure and development factors)? Specifically, have soft tissues been preserved on the image or has the detector been saturated resulting in loss of soft tissue visualization?
2. Is the correct anatomy present within the image?
3. Is the positioning correct for the radiographic projection?

Once the desired technique has been attained, make sure the appropriate anatomy is included. The mediolateral and dorsopalmar projections of the carpus, manus, and phalanges should include the following areas:

Carpus

- On the mediolateral projection of the carpus:
 - » The accessory carpal bone should not look foreshortened.
 - » No proximodistal superimposition should be present between the carpal bones; each row should be distinctly separated by a joint space (middle carpal joint).
- On the dorsopalmar projection of the carpus:
 - » The accessory carpal should appear as a rounded structure superimposed over the ulnar carpal bone.

With the advent of digital radiography, errors in radiography technique are less common; however, if anatomy is not appropriately collimated and positioning is inadequate, imaging studies may be rendered nondiagnostic.

- » No proximodistal superimposition between the carpal bones or significant lateral overlap between carpal bones within a given row (aside from the accessory carpal bone superimposed over the ulnar carpal bone) should be present.

Manus

- On the mediolateral projection of the manus:
 - » The accessory carpal bone should not look foreshortened.
 - » The proximal and distal rows of carpal bones should appear superimposed; however, each row will be distinct, with the middle carpal joint and carpometacarpal joint being separate radiolucent lines.
 - » The metacarpal bones, metacarpophalangeal joints, and phalanges should be superimposed.
- On the dorsopalmar projection of the manus:
 - » The image should include the carpus and distally

<RXU &RPSOHWH ' LJLWDO ' HQWDO 6ROXWLRO

,QFRPSDUDEOH ' LJLWDO ,PDJLQJ LQ DDO ' HQWDO 6LJHV

“Q RXU SUDFWLFH WKH JUHDW EHQHAW RI WKH 6FDQ; ' XR LV WKH IDFW WKDW LW LV VR PXFK HDVLUH WR WDNH ODUJHU YLHZV XVLQJ WKH UDQJH RI SODWH VLJHV μ

² -DQ %HQWZV ' 90
\$0 3HW ' HQWDO &LQF DQG
+RPHWRZO \$QLPDO +RVSUWDO
: HWURO)ORUGD



scan-x_{duo}
9HUVDWLOH ' LJLWDO ,PDJLQJ

\$00 <RXU ,PDJLQJ 1 HHGV LQ D 6LQJOH 6\VMHP

2XU FRPSUHKKOVLH XVHU IULHOG\ 6FDQ; ' XR &5 SDFNDJHV IQFQGH HYH\WKLQJ \RX QHHG 3\$&6PDOU RU OHWURO ,PDJLQJ 6RIWZDUH ODSWRS FRPSXWHU IPDJLQJ SODWHV DQG DFFHWRLHV

6FDQ; ' XR DW D JODQFH ([FHSWRQDO TXDQW KLK UHVROXWLRO GLJLWDOIPDJLQJ LQ DDO GHQWDO VLJHV ' XDOLPDJLQJ SODWH VFDQQLQJ FDSDELQW

' HWHFW SDWKRORJLHV XOGHU WKH JXP WKDW DUH QRW YLVEH GXILQJ D URXWLQH H[DP ZLWKRXW UDGLRJUDSKV (QKQFH SDWLHOW FDUH DQG JHOHUDWH DGGMLRQDOIQFRPH

7R OHDUQ PRUH RU WR VFKHGXI\ DQ LQ RI\FH GHPRQVMDLRO SOHDVH YLVLW ZZZ DOWSURLPDJLQJ FRP KHDOLKFDUH



to the phalanges, including the toe nails.

- » The carpus should have the same appearance as when the image is centered on the carpus.
- » The phalanges should be spread apart to avoid superimposition among them.

Phalanges

Each phalanx should be separated to allow visualization of each joint on the mediolateral and dorsopalmar projection of the phalanges. ■

FOV = field of view

Suggested Reading

- Burk RL, Feeney DA. *Small Animal Radiology and Ultrasonography: A Diagnostic Atlas and Text*, 3rd ed. Philadelphia: Saunders Elsevier, 2003.
- Kealy JK, McAllister H, Graham JP. *Diagnostic Radiology and Ultrasonography of the Dog and Cat*, 5th ed. Philadelphia: Saunders Elsevier, 2011.
- Sirois M, Anthony E, Mauragis D. *Handbook of Radiographic Positioning for Veterinary Technicians*. Clifton Park, NY: Delmar Cengage Learning, 2010.
- Thrall DE (ed). *Textbook of Veterinary Radiology*, 6th ed. Philadelphia: Saunders Elsevier (available 2013).
- Thrall DE, Robertson ID. *Atlas of Normal Radiographic Anatomy and Anatomic Variants in the Dog and Cat*. Philadelphia: Elsevier Saunders, 2011.



Danielle Mauragis, CVT, is a radiology technician at University of Florida College of Veterinary Medicine. She teaches veterinary students all aspects of the physics of diagnostic imaging, quality control of radiographs, positioning of small and large animals, and radiation safety. Ms. Mauragis coauthored the *Handbook of Radiographic Positioning for Veterinary Technicians* (2009) and was the recipient of the Florida Veterinary Medical Association's 2011 Certified Veterinary Technician of the Year Award. This award recognizes an individual for the many outstanding contributions that person has made to the overall success of a veterinary practice operated or staffed by an FVMA member veterinarian.



Clifford R. Berry, DVM, Diplomate ACVR, is a professor in diagnostic imaging at the University of Florida College of Veterinary Medicine. His research interests include cross-sectional imaging of the thorax, nuclear medicine applications in veterinary medicine, and biomedical applications of imaging in human and veterinary medicine. Dr. Berry has been a faculty member at North Carolina State University and University of Missouri. He received his DVM from University of Florida and completed a radiology residency at University of California–Davis.


(*Pet Obesity Epidemic continued from page 87*)

References

1. Hand MS, Lewis LD, Crane SW, et al. Commercial pet foods. *Small Animal Clinical Nutrition*, 5th ed. Topeka, KS: Mark Morris Institute, 2010, pp 160, 213, 502.
2. Bauer JE. Evaluation of nutraceuticals, dietary supplements, and functional food ingredients for companion animals. *JAVMA* 2001; 218(11):1755-1760.
3. McMillan FD. Development of a mental wellness program for animals. *JAVMA* 2002; 220(7):965-972.
4. Bland IM, Guthrie-Jones A, Hill TJ. Dog obesity: Veterinary practices' and owners' opinion on cause and management. *Prevent Vet Med* 2010; 94:310-315.
5. Kealy RD, Lawler DF, Ballum JM, et al. Effects of diet restriction on life span and age-related changes in dogs. *JAVMA* 2002; 220(9):1315-1320.
6. Heuberger R, Wakshlag J. The relationship of feeding patterns and obesity in dogs. *J Anim Physiol Anim Nutr* 2010; 95:98-105.
7. Courcier EA, Thomson RM, Mellor DJ, Yam PS. An epidemiological study of environmental factors associated with canine obesity. *J Small Anim Pract* 2010; 51(7):362-367.
8. Colliard L, Ancel J, Benet JJ, et al. Risk factors for obesity in dogs in France. *J Nutr* 2006; 36:S1951-S1954.
9. Steiff EL, Bauer JE. Nutrition adequacy of diets formulated for companion animals. *JAVMA* 2001; 219(5):601-604.
10. Horwitz DF. Environmental enrichment for dogs and cats. *NAVCC Clin Brief* 2007; Oct, pp 53-54.
11. Ellis SLH. Environmental enrichment: Practical strategies for improving feline welfare. *J Fel Med Surg* 2009; 11(11):901-912.
12. Shyan-Norwalt MR. Caregiver perceptions of what indoor cats do 'for fun.' *J Appl Welfare Sci* 2005; 8(3):199-209.



Laura Eirmann, DVM, Diplomate ACVN, is a clinical nutritionist at Oradell Animal Hospital in Paramus, NJ, and a veterinary communications manager with Nestlé Purina. She received her DVM from Cornell University and completed a residency in clinical nutrition under veterinary nutritionists at University of Pennsylvania, Tufts University, and Angell Memorial Animal Hospital.



Bethany Fackler is a fourth-year veterinary student at Mississippi State University College of Veterinary Medicine. She plans to obtain a residency in comparative ophthalmology and pursue a career in academia. Other areas of interest include companion animal nutrition and small animal emergency and critical care.



Joel D. Ray, DVM, MS, is an assistant clinical professor at Mississippi State University and assistant service chief for Community Veterinary Services at the MSU Animal Health Center. He coordinates the small animal internal medicine course for veterinary technology students and lectures both veterinary and graduate students. He received his DVM and MS from Mississippi State University.